

University of  
CINCINNATI Emergency Medicine



# ANNALS OF B POD

Spring 2022 (Volume XV Issue III)



*Leadership*

*Excellence*

*Opportunity*

**Editors**

---

Meaghan Frederick, MD  
Colleen Laurence, MD  
Emily Roblee, MD  
Laura Frankenfeld, MD  
Kristin Meigh, MD  
Jonathan Chuko, MD  
Arthur Broadstock, MD  
Bailee Stark, MD  
Courtney Kein, MD  
Marlena Wosiski-Kuhn, MD  
Lauren Gillespie, MD

**Faculty Editors**

---

William Knight, MD  
Natalie Kreitzer, MD  
Robbie Paulsen, MD  
Ryan LaFollette, MD  
Kari Gorder, MD  
Grace Lagasse, MD  
Jessica Baez, MD  
Sim Mand, MD

**Founding Editors**

---

Aaron Bernard, MD  
Christopher Miller, MD



**Blast Crisis**

*by:*  
*Lauren Gillespie MD*



**Polycythemia**

*by:*  
*Olivia Urbanowicz MD*



**8**

**Ocular  
Toxoplasmosis**

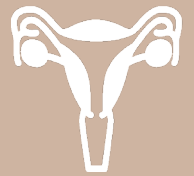*by:  
Stephanie Winslow MD*



**10**

**Aspergilloma**

*by:  
Matthew M. Mannion  
MS4*



**12**

**Fallopian Tube  
Torsion**

*by:  
Andrea Comiskey MD*





# BLAST CRISIS



Lauren Gillespie, MD  
University of Cincinnati R2

## History of Present Illness

The patient is a female in her early 20s who was referred to the emergency department (ED) by her primary care provider, who saw her earlier that day for knee pain. The patient has had pain in bilateral knees for the past two days and describes it as deep, aching, and constant. The pain is worse with ambulation and slightly improved with acetaminophen and ibuprofen. She denies any recent trauma. She has had some associated hand and ankle arthralgias as well. Earlier today, her primary care provider prescribed ketorolac and prednisone and ordered outpatient laboratory studies. She was then advised to immediately present to the ED after labs resulted and were noted to have a profoundly elevated white blood cell count. Review of systems at time of presentation to the ED is negative for headaches, vision changes, night sweats, weight loss, fever, chills, nausea, vomiting, chest pain, or dyspnea.

	T 98.6 F
	HR 90
	BP 123/88
	RR 18
	SpO2 98% on RA

**Past Medical History**  
Asthma, bipolar I disorder, post-traumatic stress disorder

**Past Surgical History**  
None

**Medications**  
Albuterol, cetirizine, vitamin D3

**Allergies**  
None

**Social History**  
No tobacco or alcohol use. Smoke marijuana regularly.

## Physical exam

The patient is a young female in no apparent distress, well-nourished without cachexia. Head, ears, eyes, nose, and throat exam reveals moist mucous membranes. Cardiopulmonary examination is unremarkable. Abdominal exam is benign without focal tenderness or distension. She has warm, dry skin without rash, petechiae, or ecchymoses. Musculoskeletal exam demonstrates no swelling, tenderness, or limitation of range of motion of bilateral knees. Neurologic exam reveals appropriate mental status, grossly intact cranial nerves, normal ambulation, and spontaneous movement of all four extremities.

## Diagnostics

<del>8.7</del>	<del>137</del>	<del>103</del>	<del>11</del>	<del>110</del>
<del>262</del>	<del>3.7</del>	<del>27</del>	<del>0.89</del>	
<del>129</del>				
<del>30.1</del>				

Differential: Myelocytes 10.5% | Metamyelocytes 3.0% | Bands 10% | Neutrophils 30.5% | Lymphocytes 4.5% | Monocytes 1.5% | Eosinophils 1.5% | Basophils 0.5% | Comments: noted to have 38% blasts on path review  
MCV 88.9 | MCH 25.8  
Phosphorus 4.2 | Magnesium 2.1  
Haptoglobin <30 (44-215 mg/dL)  
LDH 1,753 (140-280 units/L)  
Uric acid 6.5 (3.8-8.7 mg/dL)  
D dimer 6.51 | CRP 24.8 (1-10 mg/L)  
Fibrinogen 270 (218-406) | INR 1.2, PTT 36.3  
Hepatic function panel AST 50, bilirubin normal  
Blood cultures and peripheral smear pending  
Knee X rays revealed no joint effusion or evidence of acute bony abnormality

## Hospital Course

The bone marrow transplant (BMT) team had been pre-notified about the patient and admitted her to their service. They reviewed her peripheral smear and found it concerning for chronic myelogenous leukemia (CML) with blast crisis. She underwent bone marrow biopsy, flow cytometry, and chromosome analysis which were consistent with primary B-cell acute lymphoblastic leukemia, with positivity for the Philadelphia chromosome with BCR-ABL1 translocation t(9;22). She was started on hydroxyurea for cytoreduction; fluids for rehydration and hyperleukocytosis; Dasatinib for targeted therapy; steroids and allopurinol for tumor lysis syndrome prophylaxis; and bacterial, viral, and fungal antimicrobial prophylaxes.

It was at first uncertain whether this represented a de novo malignancy or whether it arose from underlying long-standing CML, however, further chart review revealed that the patient had actually had a leukocytosis with abnormal myeloid precursors for months to years, more consistent with primary CML. Lumbar puncture was performed to evaluate for malignancy and initiate intrathecal chemotherapy with methotrexate and hydrocortisone. The patient's knee pain persisted throughout hospitalization and was thought to be due to her underlying malignancy. She was ultimately discharged after her hyperleukocytosis improved with a plan to continue scheduled chemotherapy and undergo evaluation for a bone marrow transplant.

## Discussion

### Pathophysiology

Chronic myelogenous leukemia (CML) is a hematologic malignancy and myeloproliferative disorder that occurs due to a translocation between the long arms of chromosomes 9 and 22, resulting in the pathologic Philadelphia chromosome, so-named because it was discovered in Philadelphia. This translocation results in a fusion gene (BCR-ABL) that encodes a constitutively active tyrosine

kinase known as the Bcr-Abl1 protein.<sup>1,2</sup> This protein causes the uncontrolled production of dysregulated, dysfunctional cells of myeloid lineage in various stages of development, particularly matured and maturing granulocytes (figure 1). Although almost all CML cases are associated with the Philadelphia chromosome, the Philadelphia chromosome can also be present in acute lymphocytic leukemia (ALL) and acute myelogenous leukemia (AML), and its presence is not sufficient for definitive CML diagnosis.<sup>2,3</sup>

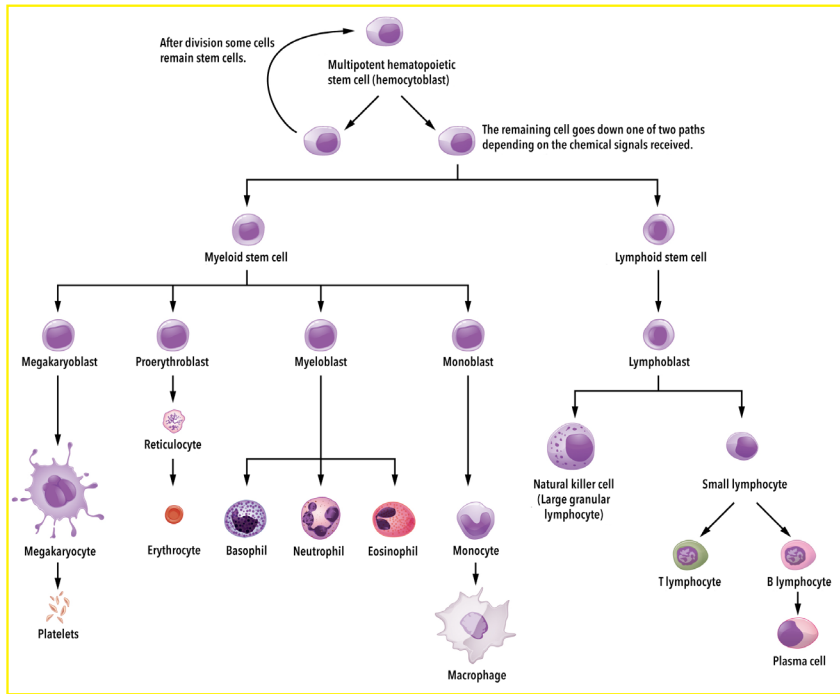


Figure 1: Normal hematopoiesis

adenopathy, and skin infiltration.<sup>2</sup> Some of the more commonly reported symptoms at the time of CML diagnosis are summarized in table 2.<sup>7</sup> A variety of additional rare presentations of CML have been reported in the literature including spontaneous splenic rupture or infarct, avascular necrosis, intracranial hemorrhage, spontaneous soft tissue hematoma, and other symptomatic bleeding and ischemic conditions.<sup>10-14</sup>

Patients in blast phase may present with hyperleukocytosis (WBC count  $>50-100 \times 10^9/L$ ) leading to leukostasis, which is a true oncologic emergency in which white blood cell infiltrates in the

microvasculature cause tissue ischemia. The pathophysiologic mechanisms underlying leukostasis are not completely understood, but are thought to include increased blood viscosity as well as endothelial damage.<sup>15</sup> Symptoms of leukostasis can involve any organ system, most commonly the central nervous system, lungs, and kidneys, and may include cerebrovascular accident, confusion, coma, acute respiratory distress, and renal failure in addition to retinal hemorrhage, priapism, tinnitus, myocardial ischemia, bowel infarction, and venous thrombosis.<sup>8,16</sup> Eighty percent of patients presenting with leukostasis have fever, likely from heightened inflammation or concurrent infection.<sup>16</sup>

### Epidemiology

CML accounts for approximately 15% of leukemia diagnoses in the Western Hemisphere,<sup>2</sup> with 1-2 cases per 100,000 people diagnosed annually.<sup>4</sup> Its prevalence is increasing due to improving survival rates with the development of more effective therapies in recent years.<sup>2</sup> CML is most common in adults with a median age at diagnosis of 66, and only 2% of cases are diagnosed in adolescents and children.<sup>4,5</sup> Risk factors for CML include exposure to ionizing radiation, gender (slightly more common in males), and older age.<sup>6</sup>

### Clinical Presentation

Patients with CML present in one of three phases: chronic phase, accelerated phase, or blast phase. Ninety percent of patients with CML are diagnosed in the chronic phase, often incidentally due to an abnormal complete blood count performed for other reasons, though most do report at least one symptom at the time of diagnosis.<sup>7,8</sup> As the disease progresses, patients may enter the accelerated phase, and then the blast phase, which are diagnoses made using laboratory and pathology studies (table 1).<sup>8,9</sup> Patients in the accelerated phase and blast phase are much more likely to have treatment-resistant disease and a poorer prognosis.<sup>8</sup>

Accelerated Phase One or more of the following	Blast Phase One or more of the following
10-19% blasts in peripheral blood or bone marrow	$>20\%$ blasts in peripheral blood or bone marrow
$>20\%$ basophils in peripheral blood	Large foci or clusters of blasts on bone marrow biopsy
$<100,000$ platelets unrelated to therapy	Presence of extramedullary blast infiltrates
Progressive splenomegaly and increasing WBC count, unresponsive to therapy	
Additional chromosome abnormalities other than Philadelphia chromosome	

Table 1: Diagnostic criteria for CML-AP and CML-BP

Early in the disease course, patients may experience generalized symptoms such as malaise, weight loss, fever, and abdominal discomfort due to developing hepatosplenomegaly associated with extramedullary hematopoiesis.<sup>8</sup> As the disease becomes more advanced, patients are more likely to experience bone pain, lymph-

### Diagnostic Workup

Patients with CML frequently present with leukocytosis ranging from  $10-500 \times 10^9/L$ . Careful examination of the white blood cell differential is extremely important, since leukocytosis can easily be attributed to infection or inflammation. In CML, the differential will show a left-shift with

predominance of neutrophils and the presence of bands, myelocytes, metamyelocytes, promyelocytes, and blasts. Absolute basophils or eosinophils may also be increased. Thrombocytosis or thrombocytopenia may be present, and anemia is present in about one-third of patients.<sup>17</sup>

A peripheral smear is also helpful in the ED to identify abnormal cellular morphology. Ultimately, a bone marrow biopsy with advanced pathology and cytogenetic testing are necessary to make the diagnosis.<sup>8</sup> If hematologic malignancy is suspected in the ED,

### Blast Crisis






Continued on page 15

# POLYCYTHEMIA

Olivia Urbanowicz MD  
University of Cincinnati R4

## History of Present Illness

The patient is an otherwise healthy female in her late 50s who presents to the emergency department (ED) with a chief complaint of bilateral posterior neck pain, odynophagia, and dysphagia with solid foods over the previous two weeks. She describes the neck pain as constant, 10/10 pain which has been progressively worsening, is exacerbated by movement, and is not alleviated by Tylenol or Ibuprofen. She also vomited twice a few days ago. She denies fever, nausea, abdominal pain, dysuria, hematuria, constipation, or diarrhea.

<b>Past Medical History</b> None	 T 97.2 F
<b>Past Surgical History</b> Hysterectomy	 HR 80
<b>Medications</b> None	 BP 150/92
<b>Allergies</b> Penicillin	 RR 16
	 SpO2 100% via RA

## Physical exam

The patient is a thin female in no acute distress. Her pupils are equal, round, and reactive to light. Cranial nerves are intact, and her voice is clear without aphasia or dysphonia. She has 5/5 strength and intact sensation throughout bilateral upper extremities. No trismus is appreciated. Mucous membranes appear dry. Range of motion of the neck is limited, but there is no nuchal rigidity. She is exquisitely tender to palpation over the paraspinal musculature and soft tissues of the neck. Cardiovascular, pulmonary, and abdominal exam are within normal limits.

## Notable Diagnostics

<del>67.1</del>				
5.4	<del>85</del>	138	101	7
		3.8	29	0.88
	<del>22.7</del>			82

Calcium 9.5, phosphate 3.4, albumin 3.7  
HIV 1+2 nonreactive

## Hospital Course

The patient was given ketorolac with subsequent improvement in her neck pain and normalization of the range of motion of her

neck. A nasopharyngeal scope was performed at bedside which showed no edema, masses or abnormalities of the vocal cords, epiglottis, or posterior pharynx. Contrasted CT imaging of the neck was normal. However, lab workup revealed an incidental finding of polycythemia. Although the workup for her neck pain was negative and her pain significantly improved, the patient was admitted to hospital medicine for further evaluation and management of her incidental polycythemia.

Hematology was consulted and recommended outpatient transthoracic echocardiography to evaluate for a shunt, carboxyhemoglobin, and JAK 2 level. Phlebotomy of 500mL was performed with replacement of crystalloid due to the extent of her polycythemia. The patient was discharged two days later, without any apparent complications, with plans to follow up in the outpatient setting with hematology for likely primary polycythemia. At that time, polycythemia vera and EPO-driven polycythemia were thought to be the most likely etiologies.

Results later demonstrated a normal echocardiogram, carboxyhemoglobin of 3.5% (normal value < 2% as the patient is not a smoker), normal JAK 2, normal EPO levels, negative testing for BCR-ABL, and CT abdomen/pelvis negative for splenomegaly. She declined bone marrow biopsy, so the etiology of her polycythemia remains unknown. She continues to be managed with intermittent phlebotomy. Since her initial visit, she has also had seizures and was found to have subdural hygromas and evidence of prior CVAs. She has also had intermittent ED visits for neck pain, which have been thought to be secondary to occipital neuralgia.

## Discussion

### Hospital Course

The patient was given ketorolac with subsequent improvement in her neck pain and normalization of the range of motion of her neck. A nasopharyngeal scope was performed at bedside which showed no edema, masses or abnormalities of the vocal cords, epiglottis, or posterior pharynx. Contrasted CT imaging of the neck was normal. However, lab workup revealed an incidental finding of polycythemia. Although the workup for her neck pain was negative and her pain significantly improved, the patient was admitted to hospital medicine for further evaluation and management of her incidental polycythemia.

Hematology was consulted and recommended outpatient transthoracic echocardiography to evaluate for a shunt, carboxyhemoglobin, and JAK 2 level. Phlebotomy of 500mL was performed with replacement of crystalloid due to the extent of her polycythemia. The patient was discharged two days later, without any

apparent complications, with plans to follow up in the outpatient setting with hematology for likely primary polycythemia. At that time, polycythemia vera and EPO-driven polycythemia were thought to be the most likely etiologies.

Results later demonstrated a normal echocardiogram, carboxyhemoglobin of 3.5% (normal value < 2% as the patient is not a smoker), normal JAK 2, normal EPO levels, negative testing for BCR-ABL, and CT abdomen/pelvis negative for splenomegaly. She declined bone marrow biopsy, so the etiology of her polycythemia remains unknown. She continues to be managed with intermittent phlebotomy. Since her initial visit, she has also had seizures and was found to have subdural hygromas and evidence of prior CVAs. She has also had intermittent ED visits for neck pain, which have been thought to be secondary to occipital neuralgia.

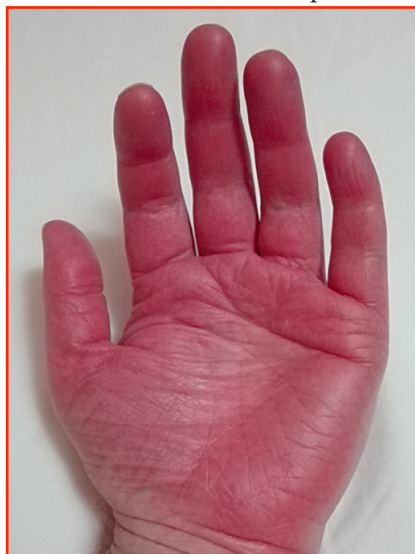

Figure 1: Erythromelalgia

### Polycythemia

Polycythemia, also called erythrocytosis, is an abnormally elevated level of hemoglobin or hematocrit in the circulating peripheral blood. Polycythemia can be classified into relative polycythemia, which is generally secondary to volume depletion, and absolute polycythemia, which can arise from primary myeloproliferative disorders or in response to hypoxia from a number of secondary causes.<sup>1</sup> Although the majority of patients are found to have polycythemia incidentally, a small percentage present to the ED with acute thrombotic events, which are a rare but well-recognized complication of both primary and secondary polycythemia.

### Pathophysiology and Definitions

Polycythemia is a laboratory-based diagnosis, defined as hemoglobin >16.5g/dL in men, >16g/dL in women or hematocrit >49% in men, >48% in women.<sup>1</sup> It is important to recognize that both hemoglobin and hematocrit are not direct measures of red blood cells (RBCs). Instead, they more accurately depict the percentage or relative value of the circulating blood volume that is comprised of RBCs. A patient can have a relative polycythemia resulting from decreased plasma volume (hemoconcentration), most commonly due to dehydration, vomiting, diarrhea or diuretic use. Although patients with polycythemia often have an elevated RBC count, the RBC count alone can be appropriately elevated in physiologic response to anemia, and therefore must be elevated in conjunction with an elevated hemoglobin or hematocrit in order to be diagnostic.

Absolute polycythemia (a true increase in red blood cell mass) can be further divided into primary and secondary causes. Primary polycythemias are caused by mutations in the RBC progenitor cells that result in an increased total RBC mass. The most well-characterized of these entities is polycythemia vera (PV), which is due to a JAK2 mutation. However, many other myeloproliferative disorders can result in primary polycythemia.

Secondary polycythemia is an increased RBC mass in response to elevated serum erythropoietin (EPO) levels, which is usually sec-

ondary to tissue hypoxia. Common preceding conditions leading to secondary polycythemia include smoking, chronic obstructive pulmonary disease, obstructive sleep apnea, and carbon monoxide exposure. Patients residing at high altitude live in a relatively hypoxic environment and can demonstrate elevated, non-pathologic baseline levels of both hemoglobin and hematocrit. In order to account for this, the reference upper limit for hemoglobin should be increased by approximately 1.0g/dl for patients living between 7500 and 10000 feet of altitude and by approximately 2.0g/dl for patients living at 10000-12000 feet.<sup>2</sup> EPO is produced by the kidneys, so patients with chronic renal insufficiency or a subacute insult to the renal parenchyma can also present with a secondary polycythemia. Secondary polycythemia may also result from EPO levels which are inappropriately elevated secondary to a paraneoplastic syndrome from an EPO-secreting malignancy. The malignancies most commonly implicated include renal cell carcinoma, hepatocellular carcinoma, and pheochromocytoma. Finally,

secondary polycythemia can be seen in athletes who undergo autologous blood transfusions or exogenous EPO administration (also known as blood doping). Regardless of the cause of an absolute polycythemia, the increased RBC mass leads to hyperviscosity of the blood, placing the patient at increased risk of thrombotic events.

### Clinical Presentation

In the Emergency Department, polycythemia most often presents as an incidental finding. It is important to attempt to differentiate between relative and absolute polycythemia, as only the latter confers a significant thrombotic risk. This can be accomplished by treating with intravenous fluids and retesting; improvement following fluid resuscitation indicates a relative polycythemia. In addition to volume depletion, chronic carbon monoxide exposure (such as smoking history or environmental exposures), chronic hypoxia, and occult malignancy should all be considered during the initial evaluation of a patient with undifferentiated polycythemia.

<b>Central Nervous System</b>	Fatigue, headache, dizziness
<b>Peripheral Nervous System</b>	Paresthesias, weakness
<b>Thoracic</b>	Chest pain, shortness of breath
<b>Gastrointestinal</b>	Abdominal pain, history of or current peptic ulcer disease/gastro-duodenal erosions, early satiety
<b>Skin/Musculoskeletal</b>	Myalgias, erythromelalgia, ruddy facies
<b>Vision</b>	Transient vision loss, blurred vision
<b>Psychiatric</b>	Depression or depersonalization, slow mentation

Table: Hyperviscosity symptoms by system

Patients with absolute polycythemia may present with symptoms of hyperviscosity (see table). Specific symptoms in polycythemia vera include pruritus after bathing (either with hot or cold water) and erythromelalgia (figure 1). Some studies suggest these symp-

### Polycythemia

Continued on page 15

# OCULAR TOXOPLASMOSES

Stephanie Winslow  
University of Cincinnati R3

## History of Present Illness

The patient is a male in his late teens who presents to the emergency department with a chief complaint of right eye redness, pain, and blurred vision for one week. There are no associated floaters or photophobia. Additional complaints include rash and nausea with one episode of vomiting. The patient is originally from Nicaragua and moved to the United States one month ago. He was previously seen by a physician in Nicaragua for the same complaint and was diagnosed with an eye infection, but he is not sure what type. He was started on trimethoprim-sulfamethoxazole, pyrimethamine and steroid eye drops. The patient has worked with fiberglass in the past, but is unsure of any ocular foreign bodies. He is not a contact lens wearer and denies any history of trauma.

## Past Medical History/Past Surgical History

None






## Medications

Trimethoprim-sulfamethoxazole, pyrimethamine, ophthalmic dexamethasone drops

## Allergies

None

## Physical Exam

 T 100.1  
 HR 130  
 BP 116/52  
 RR 19  
 SpO2 99% on RA

The patient is a well-appearing male in no acute distress. Eye exam reveals diffuse injection of the conjunctiva of the right eye. Pupils are 4mm, equal, and briskly reactive to direct and consensual light stimulation. Slit lamp exam reveals no fluorescein uptake, foreign body, or cell and flare. The iris and lens appear normal. Left eye visual acuity is 20/25. Right eye visual acuity is counting fingers at 5 feet. Cardiovascular exam is remarkable for tachycardia. Pulmonary, abdominal, musculoskeletal exams are unremarkable. The skin exam shows a maculopapular rash of the trunk. Neurologic exam is within normal limits.

## Notable Diagnostics

AST 55, ALT 66, Total Bilirubin 0.5  
WBC 8.0, HIV non-reactive

Chest X-ray: No acute cardiopulmonary abnormality

## Hospital Course

Ophthalmology was consulted from the emergency department. On their dilated fundoscopic exam they observed white chorioretinal lesions in the posterior pole near the fovea and along the superior arcade. Given the patient's history of treatment with trimethoprim-sulfamethoxazole, pyrimethamine, and topical dexamethasone, ophthalmology felt the patient's presentation was

most consistent with a diagnosis of ocular toxoplasmosis. However, on their exam ocular toxoplasmosis did not appear active, and recommended testing for syphilis and tuberculosis. In the ED, the patient was initiated on prednisolone eye drops, trimethoprim-sulfamethoxazole was continued for one week, and pyrimethamine was discontinued. The patient was seen by ophthalmology in follow-up as an outpatient one week later. His ocular lesions were found to be stable, consistent with inactive ocular toxoplasmosis. The patient ultimately returned to Nicaragua and was lost to further follow-up.

## Discussion

### *Toxoplasma gondii* Life Cycle and Epidemiology

*Toxoplasma gondii* is a ubiquitous obligate intracellular protozoan parasite that infects many species, including humans, and is the most common cause of infectious posterior uveitis in the world.<sup>1</sup> Cats are the definitive or primary hosts for *T. gondii*, and they are the only organism in which the *T. gondii* sexual reproductive cycle takes place. Infected cats release toxoplasma oocytes in their feces. Intermediate hosts, such as pigs or humans, become infected with toxoplasma by consuming food or water contaminated with cat feces, eating undercooked meat containing tissue cysts, through blood transfusion or organ transplant, or congenitally from mother to fetus.<sup>2</sup> (Figure 1) Once ingested by an intermediate host the oocytes then become infectious tachyzoites, which multiply rapidly by an asexual reproductive cycle, causing local tissue destruction and inflammation. Under the pressure of a competent immune system, tachyzoites become bradyzoites, a dormant version, which form tissue cysts that can persist for the life of the host.

Approximately 25-30% of the human population is infected with *T. gondii*, however, rates of seropositivity for this infection vary greatly based on socioeconomic factors, hygiene, and climate, with higher rates of seropositivity in warmer geographic locations.<sup>1</sup> In the United States, it is estimated that approximately 1 million people are seropositive for *T. gondii*, and approximately 20,000 people have ocular toxoplasma lesions.<sup>3</sup>

### Clinical Presentation

Acute acquired infection with *T. gondii* (toxoplasmosis) in immunocompetent patients is often asymptomatic, however, approximately 10% of patients will develop a nonspecific flu-like illness, which is usually self-limited. The most common systemic finding in immunocompetent patients with acute toxoplasmosis is painless, non-suppurative lymphadenopathy, usually cervical or occipital. Rarely, toxoplasmosis can present as myocarditis, polymyositis, pneumonitis, hepatitis, or encephalitis in immunocompetent patients.<sup>4</sup>

In immunocompromised patients, toxoplasmosis is often symptomatic and can be life-threatening. It usually occurs as a reacti-



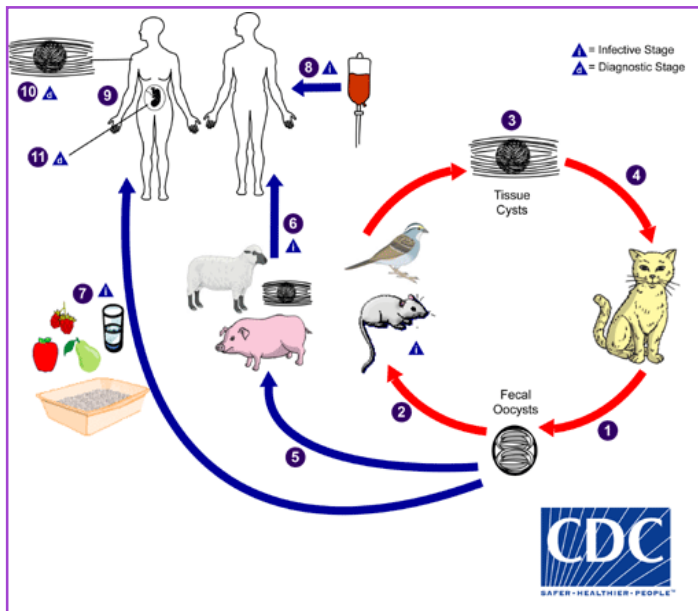


Figure 1: Life cycle of *T. gondii*.

vation of latent infection, rather than an acute infection. *T. gondii* has a predilection for neurologic tissue, and the central nervous system is commonly affected. A wide variety of neuropsychiatric symptoms may be seen, including mental status changes, seizures, focal neuro deficits, movement disorders, and behavioral changes. Patients can also present with pneumonitis, chorioretinitis, and even multiorgan failure similar to septic shock.<sup>4</sup>

Congenital toxoplasmosis occurs when a pregnant patient becomes acutely infected during her pregnancy, allowing infectious tachyzoites to be transmitted via the bloodstream to the fetus. Previously-acquired latent infection poses little to no risk to the fetus, since the parasites in latent infection exist in tissue cyst form. Manifestations of congenital toxoplasmosis include hydrocephalus, microcephaly, intracranial calcifications, chorioretinitis, strabismus, blindness, epilepsy, mental retardation, thrombocytopenia, and anemia.<sup>4</sup>

### Ocular Toxoplasmosis

Ocular toxoplasmosis typically presents as posterior uveitis, with the potential for inflammation of the choroid, retina, and optic nerve.<sup>3</sup> It occurs due to both congenital and acquired infections.<sup>5</sup> Patients may experience floaters and vision loss, and vision can be rapidly and profoundly affected, with up to 24% of patients presenting with visual acuity worse than 20/200 at some point over the course of their disease.<sup>6</sup> Clinical diagnosis of ocular toxoplasmosis is highly dependent upon the dilated ophthalmologic exam. The classic fundoscopic finding for ocular toxoplasmosis is fluffy, white, focal, necrotizing retinitis. The active lesion is often obscured by severe inflammation of the vitreous, causing a “headlight in the fog” appearance (Figure 2). Significant scarring of the retina, particularly in the macula, can also be seen (Figure 3).

Differential diagnosis for the presentation of ocular toxoplasmosis includes other causes of posterior uveitis such as cytomegalovirus, herpes simplex, herpes zoster, tuberculosis, and syphilis. Alternatively, one must consider retinal detachment and diseases of the retinal vasculature in the presentation of patients with vision loss.<sup>7</sup>

### Diagnostics

If toxoplasmosis is suspected, the diagnostic testing strategy varies depending on whether the patient is immunocompetent, immunocompromised, pregnant, or newborn. Detection methods include both direct detection (using PCR or immunohistochemistry tests) and indirect detection (using serology tests for IgG, IgM, and IgA antibodies).<sup>4</sup> Serum IgG and IgM antibodies to *T. gondii* typically will begin to develop within 7-14 days after the initial infection. Serum IgM antibody positivity is the preferred marker of acute infection with toxoplasmosis. However, a high false positive rate limits its use, and its greatest value lies in the fact that a negative IgM antibody essentially rules out a recently acquired toxoplasma infection.<sup>4,8</sup> In immunocompromised patients, direct detection of toxoplasma using PCR tests in the affected body fluid (blood, bronchoalveolar lavage, pleural, peritoneal, cerebrospinal, or ocular fluids) is often an important diagnostic aid.<sup>4</sup> The diagnosis of ocular toxoplasmosis is often clinical, but in the case of uncertain diagnosis or inadequate response to treatment, serology testing or sampling of ocular fluids for direct testing may be necessary. If there is any concern for involvement of the central nervous system, CT and MRI imaging of the brain and spine are necessary, and may show characteristic “ring-enhancing” lesions.<sup>4</sup>

### Treatment

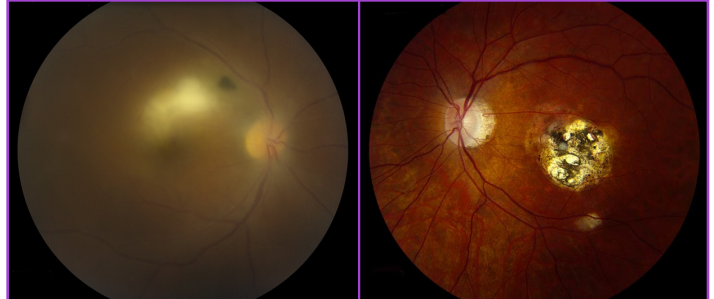


Figure 2 (left): The “headlight in the fog” sign seen on fundoscopic exam.

Figure 3 (right): Inactive toxoplasmosis lesions appearing as retinal scar.

Toxoplasmosis, including ocular toxoplasmosis, in the immunocompetent patient is usually self-limited and not treated unless symptoms are severe or prolonged.<sup>4,9</sup> Strict indications for treatment of ocular toxoplasmosis in the immunocompetent patient depend on the size of the lesion (greater than two times the diameter of the optic disc) or the location of the lesion adjacent to the optic disc to minimize vision loss.<sup>10</sup>

Empiric treatment for toxoplasmosis in non-pregnant patients, including neonates and immunocompromised patients, includes pyrimethamine, sulfadiazine, and folinic acid. The duration of treatment is variable.<sup>4</sup> Some studies have suggested that replacing pyrimethamine and sulfadiazine may also be an adequate treatment regimen.<sup>11</sup> In pregnant patients with active infection, spiramycin alone is used in the first trimester. Pyrimethamine and sulfadiazine can be started after the first trimester.<sup>4</sup> Steroids, which are thought to help to suppress inflammation in the eye, are typically added in treatment of ocular toxoplasmosis. The ideal timing, dosage, and indication for steroid use is unclear and there are a wide variety of practice patterns.<sup>12</sup> Most clinicians opt to delay the initiation of steroids at least 1-3 days after starting antiparasitic agents, since steroids can worsen optic lesions without concomitant antiparasitic use.<sup>13</sup>

### Ocular Toxoplasmosis

Continued on page 16



# ASPERGILLOMA

Matthew M. Mannion  
Southern Illinois Medical School MS-4

## History of Present Illness

The patient is a male in his late 40s with a past medical history of pulmonary sarcoidosis who presents reporting hemoptysis upon waking each morning for the past three days. He describes the hemoptysis as one to two small teaspoons of blood mixed into his sputum. Last night he coughed up a larger amount of blood, about 3-4 tablespoons, and developed pleuritic chest pain, which prompted him to come to the Emergency Department. He continues to expectorate blood-mixed sputum at bedside. His pulmonologist prescribed levofloxacin for a possible bacterial infection, which he has been taking for the past three days. He endorses his baseline dyspnea and chest tightness, but denies fever, fatigue, nausea, vomiting, melena, hematochezia, or other changes in bowel or urinary habits.

## Past Medical History

Pulmonary sarcoidosis, seasonal allergies

## Past Surgical History

Right lung biopsy in 2015

## Medications

Albuterol PRN, azathioprine 50 mg daily, budesonide-formoterol daily, cetirizine 10 mg daily, levofloxacin 500 mg daily, prednisone 20 mg daily

## Allergies

None



T 99.1 F



HR 121



BP 142/93



RR 16




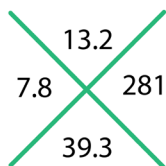
94% on RA

## Physical Exam

The patient is a well-appearing male in no acute distress. His oropharyngeal exam is unremarkable with no evidence of blood, erythema, or swelling in the posterior oropharynx or in the nares bilaterally. He has unlabored breathing with diffuse expiratory wheezes appreciated bilaterally but otherwise without focality. Auscultation of the heart reveals no murmurs, rubs, or gallops, and abdominal exam is unremarkable. All four extremities are symmetric, warm, well-perfused, and without edema. His skin is dry with no rashes or peripheral edema noted.

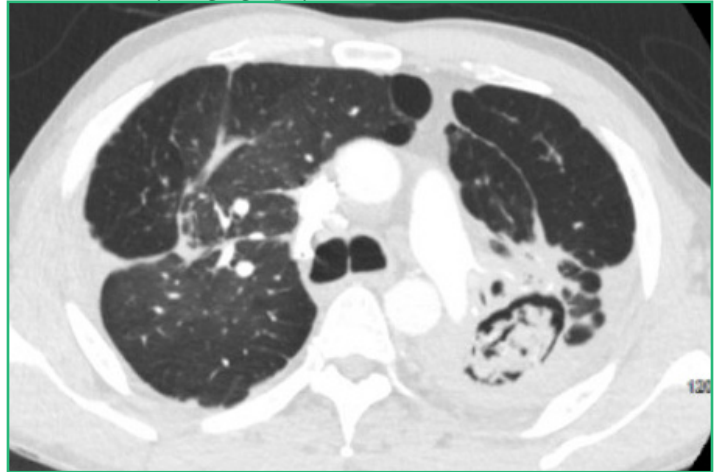
## Diagnostic Tests

Venous blood gas: pH 7.38, pCO<sub>2</sub> 50 HCO<sub>3</sub> 29, BE 3.1



Chest X-ray: Consolidation and architectural distortion most pronounced in left upper lung, similar to prior CXR, consistent with diagnosis of sarcoidosis.

CT Pulmonary Angiography:



1. No acute pulmonary embolism. 2. Posterior left upper lobe cavitation with central soft tissue mass surrounded by a crescent of air suggestive of an aspergilloma. Some linear high-density foci within the cavitory lesion may represent areas of active extravasation or abnormal irregular pulmonary arteries in the setting of hemoptysis. 3. Background of sarcoidosis. 4. Enlarged pulmonary artery can be seen in the setting of pulmonary hypertension.

## Hospital Course

Given the patient's risk factors for pulmonary embolism, he underwent CT pulmonary angiography which showed no evidence of pulmonary embolism but did reveal a 5.5 x 3 cm cavitory lesion consistent with likely aspergilloma with active bleeding into the left upper lung. He continued to have hemoptysis in the ED and was admitted to the medicine stepdown unit for close monitoring. The infectious disease (ID) team was consulted and recommended empiric treatment with voriconazole. The interventional pulmonology (IP) team performed a bronchoscopy which showed a cavitory lesion in the left upper lobe with a fungal ball. Bronchoalveolar lavage (BAL) with lung biopsy showed fungal hyphae morphologically consistent with aspergillus species, without evidence of vascular or tissue invasion. Fungal cultures eventually grew *Aspergillus fumigatus*. The remainder of the patient's infectious workup was negative, including evaluation for HIV, tuberculosis, histoplasma, and cryptococcus.

Following his bronchoscopy and biopsy, the patient developed an increased oxygen requirement but was eventually weaned down to nasal canula oxygen at 1 liter per minute. The patient was evaluated by thoracic surgery for possible surgical resection of his aspergilloma, but unfortunately was not a candidate for intervention

due to his severe pulmonary disease. The patient was discharged on home oxygen therapy and voriconazole, with plan to continue voriconazole indefinitely. Two months after this hospitalization, he had another episode of hemoptysis and underwent repeat bronchoscopy with voriconazole instillation. This procedure was repeated about one month later and since then, he has had no further hemoptysis recorded in our electronic medical record.

## Discussion

### Aspergillosis Pathophysiology and Risk Factors

Aspergillosis refers to a spectrum of disease caused by the aspergillus species of fungus, most commonly *Aspergillus fumigatus* (figure 1). *Aspergillus* is ubiquitous in our environment, living in soil and decomposing vegetation, and we are constantly inhaling its spores. Our immune systems have evolved to control the growth of aspergillus and prevent inflammation and injury from its presence, so that systemic fungal disease is uncommon. Disorders of immunity, however, can place patients at risk for infections due to aspergillus.<sup>1</sup> The type of aspergillus infection that occurs depends on host risk factors and most commonly involves the respiratory tract, although disseminated forms of the disease can occur as well.<sup>2,3</sup>

The most feared presentation of aspergillosis is invasive pulmonary aspergillosis (IPA) which is classically seen in severely immunocompromised patients. Risk factors for IPA include severe or prolonged neutropenia, defects in cell-mediated immunity (such as human immunodeficiency virus), immunosuppressive therapy, bone marrow transplant, and solid organ transplant. Patients with prolonged stays in intensive care units have also been recently identified as a population at risk for IPA, particularly those with chronic obstructive pulmonary disease with steroid use, structural lung disease, acute respiratory distress syndrome, and impaired mucociliary clearance following infection. Multiple respiratory viral infections have been associated with IPA including avian flu, influenza A and B, respiratory syncytial virus, and COVID-19. These viruses are thought to cause epithelial damage that then allows invasion by colonizing aspergillus species.<sup>3</sup>

There are multiple chronic forms of pulmonary aspergillosis that occur in patients with underlying pulmonary disease, in some cases leading to inflammation, tissue destruction, fibrosis, and worsening pulmonary function. The most common manifestation of chronic pulmonary aspergillosis is aspergilloma, also known as a mycetoma or fungus ball, in which the fungus is able to grow inside a pre-existing cavitory lesion (secondary to chronic obstructive pulmonary disease, prior tuberculosis, sarcoidosis, or other causes).<sup>3,4</sup> An association between sarcoidosis and aspergilloma has been demonstrated in the literature, with an estimated 0.7-5% of sarcoidosis patients being affected by aspergilloma.<sup>5-7</sup>

Another distinct presentation of aspergillosis is allergic bronchopulmonary aspergillosis (ABPA), which occurs almost exclusively in patients with asthma and cystic fibrosis due to a hypersensitivity reaction to *Aspergillus* species in the lungs. ABPA leads to chronic immune activation and presents with fleeting pulmonary infiltrates, worsening of reactive airway disease, and bronchiectasis.<sup>8</sup> There are multiple pulmonary aspergillus overlap syndromes, and patients may develop more than one manifestation

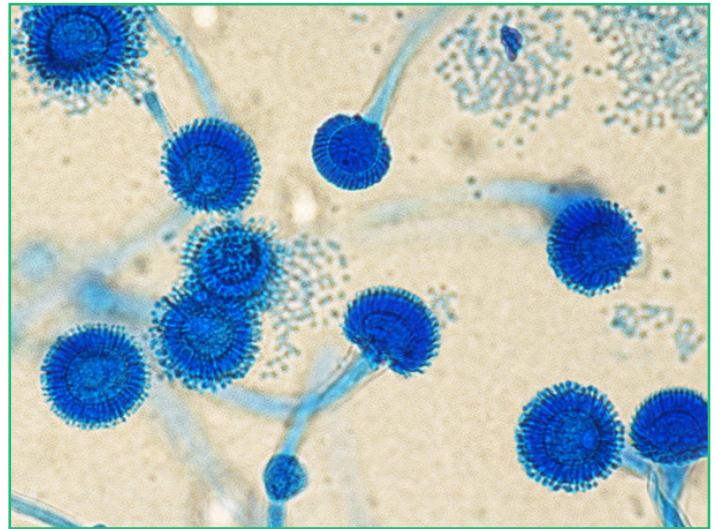


Figure 1: *Aspergillus fumigatus*

of aspergillosis or may progress from one form to another. For example, patients with ABPA and chronic pulmonary aspergillosis have gone on to develop fungal balls and IPA.<sup>9</sup> A summary of the spectrum of pulmonary aspergillosis according to risk factor is provided in Table 1.

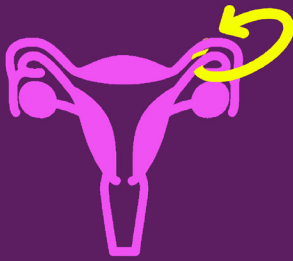
The remainder of this review will focus on pulmonary aspergilloma, since that is the most common manifestation of pulmonary aspergillosis and the entity with which our patient presented.

### Aspergilloma - Clinical Presentation

Hemoptysis is the most common clinical manifestation of aspergillomas, and aspergillomas remain one of the leading causes of hemoptysis worldwide (along with tuberculosis and lung abscess). In case series describing aspergilloma, the incidence of hemoptysis has been reported to range from 54%-87.5%, with up to 30% of patients experiencing massive fatal hemorrhage.<sup>10-12</sup> The hemoptysis is thought to be secondary to direct invasion of the capillaries lining the cavity wall, endotoxin-mediated inflammation, or mechanical irritation of exposed vessels within the cavity.<sup>9,10</sup> Symptoms can also include malaise, weight loss, chest pain, dyspnea, chronic cough, and, rarely, fever.<sup>10</sup> Aspergillomas may remain stable, or they may grow, causing pneumonia, pulmonary fibrosis, and disseminated disease (such as IPA).<sup>10</sup>

### Aspergilloma - Diagnosis

The diagnosis of aspergilloma should be considered in a patient with hemoptysis and other risk factors, and the first step for diagnosis in the emergency department is identifying radiographic evidence of a rounded fungal ball inside a cavity on chest X-ray or computed tomography. Two radiographic signs may aid in the diagnosis: the air crescent sign, which is a crescent-shaped air space separating the fungal ball from the cavity wall, and Monod sign, which is characterized by the change in position of the fungal ball depending on the patient's position. If a fungal ball is seen on imaging, the diagnosis can be confirmed with serum tests, which may include *Aspergillus*-specific IgG or IgE antibodies. *Aspergillus* cell wall components (such as galactomannan) may also be found in BAL fluid. A fungal culture positive for aspergillus species may aid in the diagnosis, but is not sufficient for diagnosis on its own since



# FALLOPIAN TUBE TORSION

Andrea Comiskey  
University of Cincinnati R3

## History of Present Illness

The patient is a 10-year-old female who presents to the emergency department for a 2-day history of abdominal pain. The pain started in the periumbilical region and migrated to the right lower quadrant. She associates her pain with mild nausea, nonbilious and non-bloodly vomiting, constipation and a low-grade temperature. The patient denies any aggravating or alleviating factors, as well as any associated dizziness, headaches, chest pain, shortness of breath, urinary frequency or dysuria, bloody stools, weight loss, back pain or additional symptoms.

## Past Medical History

Cardiac murmur, ADHD. Immunizations are up to date.

## Past Surgical History

None

## Medications

Methylphenidate 10mg by mouth daily, Miralax 8.5 gm by mouth PRN






## Allergies

No known drug allergies

## Social History

Lives at home with parents

## Physical Exam

	T 99.3	The patient is a well-developed, well-nourished young female who is oriented to person, place, and time and in no acute distress. Her abdomen is soft with right lower quadrant tenderness without rebound, rigidity or guarding. The remainder of her exam, including HEENT, cardiopulmonary, skin, extremities, and neurologic exam was unremarkable.
	HR 99	
	BP 133/76	
	RR 16	
	SpO2 99% on RA	

## Diagnostic Tests

<del>14.3</del>	<del>260</del>	140	106	7	135
8.7	41.6	3.7	29	0.35	

Urinalysis: normal

RLQ ultrasound: Appendix not visualized; no secondary signs of appendicitis noted. Abnormal configuration of the right ovary with what appears to be a serpiginous tubular structure extending from the ovary towards the uterus which may represent abnormal configuration of the fallopian tube.

Pelvis ultrasound with doppler: Situated between the right ovary and the uterus there is a dilated anechoic tubular structure which appears to be folded upon itself. This is concerning for torsion of the right fallopian tube.

## Hospital Course

In the emergency department, the providers were initially concerned for appendicitis or ovarian torsion since the patient had tenderness in the right lower quadrant coupled with nausea and vomiting. The patient underwent a dedicated right lower quadrant ultrasound to assess for appendicitis, which did not visualize the appendix but showed abnormal appearance of the right ovary with a serpiginous structure extending from the ovary to the uterus. The patient then underwent a dedicated pelvis ultrasound which demonstrated a tubular structure twisted upon itself, concerning for fallopian tube torsion.

Gynecology evaluated the patient and recommended urgent surgical exploration. Intra-operative findings included a visualized appendix with normal appearance; however, the right fallopian tube was noted to have twisted upon itself twice, with edema, loss of architecture and dusky appearance concerning for irreparable tissue damage. The patient underwent an uncomplicated right salpingectomy and cystectomy on the right. A fluid-filled mass within the tube was evacuated and after pathologic evaluation, the contents were found to be consistent with a simple cyst. The patient was discharged in stable condition from the post-operative anesthesia care unit. Two weeks after discharge she was noted to be doing well with complete resolution of her symptoms.

## Discussion

### Epidemiology

Isolated fallopian tube torsion is a rare pathology, first described by John Bland-Sutton in 18901 and currently estimated to affect approximately 1 in 1.5 million women.<sup>2</sup> Women of child-bearing age tend to present most commonly, and there are very few cases in the literature reporting this pathology in premenarchal patients.<sup>3</sup> It is also extremely rare in postmenopausal females, and the lower incidence in this population is thought to be due to fallopian tube hypotrophy and decreased blood supply.<sup>1</sup>

### Pathophysiology

Multiple mechanisms, both intrinsic and extrinsic to the fallopian tube, are proposed to cause isolated fallopian tube torsion (table 1).

In our patient, a cyst-like structure in the fimbriated half of the fallopian tube was found during laparoscopy. This may have been a hydatid cyst of Morgagni (image 1), which is a Wolffian duct remnant presenting as a simple cyst filled with serous fluid near the fimbriated ends of the fallopian tube.<sup>4</sup>

Predisposing factors for fallopian tube torsion <sup>3</sup>	
Intrinsic factors	Extrinsic factors
Congenital malformations (i.e. long mesosalpinx, hydatid cyst of Morgagni)	Paraovarian or paratubal mass
Hydrosalpinx	Uterine enlargement (i.e. pregnancy, tumor)
Tubal ligation	Adhesions (i.e. prior surgery, pelvic inflammatory disease, tuberculosis)
Tubal neoplasm	Hemodynamic alterations causing congestion and tortuosity of mesosalpingeal veins
Abnormal peristalsis or spasm (due to autonomic dysfunction or drugs)	Sudden changes in body position or trauma
Hypermobility	Increased tubal motility at midcycle

Table 1

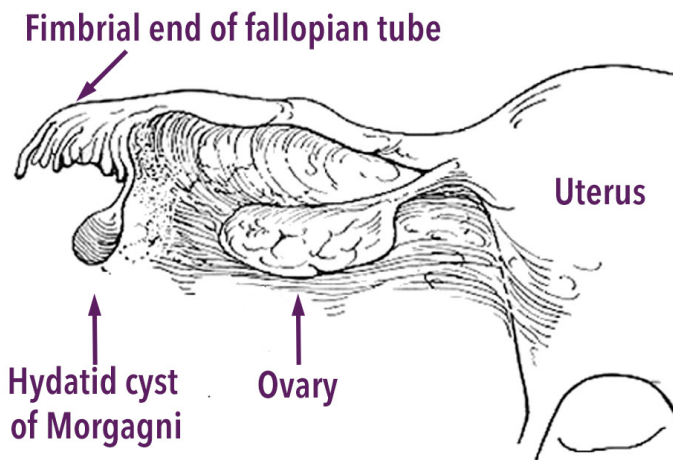


Image 1: Hydatid cyst of Morgagni

### Clinical Presentation

Fallopian tube torsion most commonly presents as lower abdominal or pelvic pain, which can radiate to the flank, thigh, or groin and can be accompanied by vomiting, vaginal bleeding, fever, tachycardia, and leukocytosis.<sup>5,6</sup> Diagnosis can be challenging since there are no pathognomonic signs or symptoms for tubal torsion, and it can mimic appendicitis, ovarian torsion, and other common causes of abdominal pain. It more commonly occurs on the right than on the left, and this is theorized to be due to the sigmoid colon and mesentery stabilizing the left fallopian tube. However, some believe that right tubal torsion is detected more often since patients with right-sided abdominal pain are imaged and surgically explored more frequently due to the concern for appendicitis.<sup>6</sup>

### Diagnostics

There are no reliable imaging modalities to identify isolated fallopian tube torsion and the diagnosis is often made by laparoscopy.<sup>6</sup> Sonography is frequently ordered to exclude ovarian torsion, and accurately predicts the diagnosis of fallopian tube torsion about 30% of the time.<sup>7</sup> Findings in isolated tube torsion are non-specific and can include free fluid, a dilated tube with thickened walls, internal debris, an echogenic mass (representing the torsed tube), or impedance, absence, or reversal of diastolic blood flow with doppler. The “whirlpool sign,” which is seen in ovarian torsion and represents the twisted blood vessels of the torsed structure, has also been demonstrated in isolated fallopian tube torsion.<sup>6,7</sup> CT scan or MRI may also be performed and can show tubal coiling, a torsion knot, infarction of the tubal walls, free fluid, peritubular fat stranding, thickening of the broad ligament, and regional ileus. may show a cystic mass or dilated tubular structure.<sup>3</sup> Laboratory studies are usually within normal limits unless there is significant necrosis or ischemia.<sup>8</sup>

### Treatment

Rapid treatment of fallopian tube torsion is essential, as it can lead to necrosis, gangrenous transformation, superinfection and peritonitis.<sup>6</sup> Once there is a high enough clinical suspicion or a confirmed diagnosis via ultrasound, gynecology should be consulted for definitive management. Laparoscopy is the gold standard for both diagnosis and treatment of tubal torsion. Laparoscopic detorsion is the preferred management if there is low concern for tissue ischemia in order to preserve fertility. However, if the tube appears necrotic, salpingectomy should be performed.<sup>9</sup>

### Summary

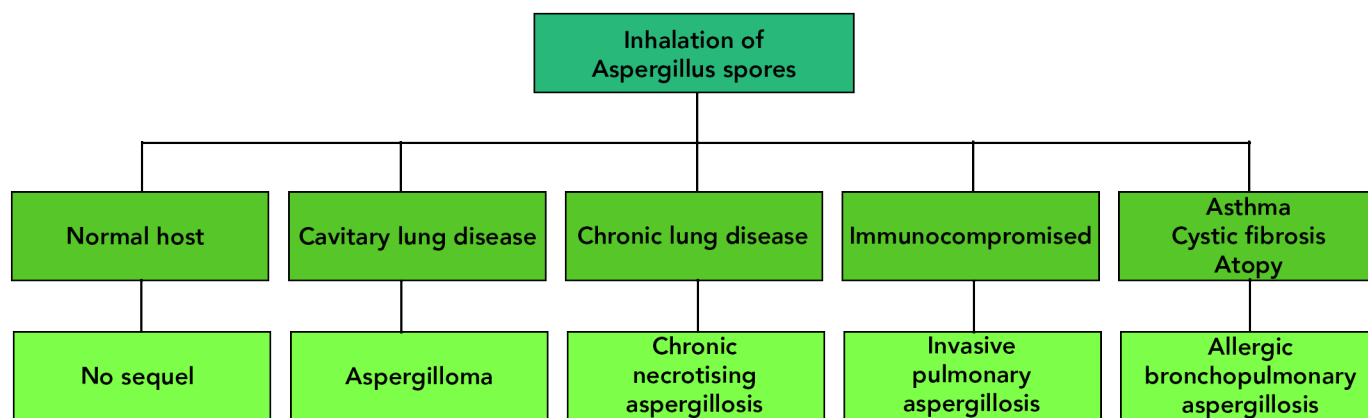
Isolated fallopian tube torsion is a rare diagnosis that should be considered in any female presenting with lower abdominal pain. Physical exam, laboratory and imaging studies are of limited utility to rule in the diagnosis, but always important for ruling out or decreasing suspicion for other pathology. The best imaging modality for detecting isolated fallopian tube torsion is ultrasound; however, the ultimate diagnosis is usually made with direct visualization by laparoscopy performed by our gynecology colleagues. Treatment consists of salpingectomy or, in the premenarchal or child-bearing population, surgical detorsion if possible in order to preserve fertility.

### References

- Toyoshima M, Mori H, Kudo K, Yodogawa Y, Sato K, Kudo T, Igeta S, Makino H, Shima T, Matsuura R, Ishigaki N. Isolated torsion of the fallopian tube in a menopausal woman and a pre-pubertal girl: two case reports. *Journal of medical case reports*. 2015 Dec 1;9(1):258.
- Schrager J, Robles G, Platz T. Isolated fallopian tube torsion: a rare entity in a premenarcheal female. *The American Surgeon*. 2012 Feb 1;78(2):E118.
- Van der Zanden M, Nap A, Van Kints M. Isolated torsion of the fallopian tube: a case report and review of the literature. *European Journal of Pediatrics*. 2011 Oct 1;170(10):1329-32.
- Perlman S, Hertweck P, Fallat ME. Paratubal and tubal abnormalities. *Seminars in pediatric surgery*. 2005 May 1;14(2):124-34.
- Bora SA, Kanathippillai R, Backos M. Isolated fallopian tube torsion: an unusual cause of acute abdominal pain. *Case Reports*. 2010 Dec 31;2011.
- Gross M, Blumstein SL, Chow LC. Isolated fallopian tube torsion: a rare twist on a common theme. *American Journal of Roentgenology*. 2005 Dec;185(6):1590-2.
- Raban O, Zilber H, Hadar E, Efrat Z, Krissi H, Wiznitzer A, Meizner I, Bardin R. Isolated fallopian tube torsion: a unique ultrasound identity or a serial copycat?. *Journal of Ultrasound in Medicine*. 2018 Oct;37(10):2387-93.
- Kardakis S, Barranca A, Vitelli A, Amore I, Trento F, Caccia G. Isolated fallopian tube torsion. *Case reports in obstetrics and gynecology*. 2013 Jul 30;2013.
- Hosni W, Schmidt CM. Isolated Fallopian Tube Torsion: A Rare Cause of Acute Abdominal Pain. *Obstet Gynecol Cases Rev*. 2019;6:151

Risk Factor	Example of predisposing risk factors	Aspergillosis Manifestation
Cavitary lung disease	Pulmonary tuberculosis, chronic obstructive pulmonary disease, sarcoidosis	Asperiglloma
Chronic lung disease	Allergic bronchopulmonary aspergillus (ABPA), chronic obstructive pulmonary disease, lung transplant, recurrent lower respiratory tract infections	Chronic pulmonary aspergillosis
Immunocompromise	Neutropenia, bone marrow transplant, solid organ transplant, hematologic malignancy, immunodeficiency syndromes, prolonged steroid treatment or other immunosuppressants	Invasive pulmonary aspergillosis
Critical Illness	Prolonged ICU stay, severe lower respiratory tract infection, acute respiratory distress syndrome	Invasive pulmonary aspergillosis
Airway hypersensitivity	Asthma, cystic fibrosis (CF), blood eosinophil counts >500 cells/L	Allergic bronchopulmonary aspergillosis (ABPA)

Table 1: Spectrum of pulmonary aspergillosis by risk factor



Spectrum of pulmonary aspergillosis

airway colonization by aspergillus species is common.<sup>13</sup>

**Aspergilloma - Treatment**

In the emergency department, treatment of an aspergilloma may involve initiation of an antifungal medication along with supportive care, especially if the patient has significant hemoptysis. Ultimately, surgical resection is the gold standard of treatment for symptomatic aspergilloma, but many patients are poor candidates for surgery due to underlying lung disease, and morbidity and mortality with surgery is considerable.<sup>13</sup> Bronchial artery embolization by interventional radiology is a potential treatment strategy for patients with moderate to severe hemoptysis who are poor surgical candidates.<sup>14</sup>

Systemic antifungal medications, including amphotericin B and azoles, have been used in patients with aspergilloma. Amphotericin B has been shown to have a cure rate of approximately 10%, which is similar to the rate of spontaneous resolution. A multicenter randomized clinical trial using itraconazole for 6 months demonstrated a cure rate of 63.4%. Voriconazole is an alternative therapy that has also shown efficacy in treatment of IPA and may have a higher threshold for fungal resistance.<sup>13,15</sup> Currently, guidelines recommend treatment of chronic pulmonary aspergillosis, including aspergilloma, with at least 6 months of azole therapy.<sup>15,16</sup> Echinocandins, such as micafungin, are also an option in patients who have previously not responded well to azoles.<sup>17</sup>

For patients who fail systemic therapy and are not surgical can-

didates, a few other treatment options remain. Endobronchial instillation of voriconazole has been effective, with 30.6% of patients reporting resolution of hemoptysis after one treatment and an additional 37.8% reporting resolution after the second treatment.<sup>18</sup> Percutaneous intracavitary instillation of antifungals has also been used with some improvement. In some cases, bronchoscopic removal of the aspergilloma may be possible.<sup>13</sup>

**Summary**

Aspergillosis is disease primarily of the respiratory tract caused by Aspergillus species in patients with underlying risk factors such as immunosuppression and structural lung disease. Aspergilloma is one manifestation of aspergillosis, in which a fungal ball develops in a preexisting cavitary lung lesion. Aspergillomas can cause life-threatening hemoptysis. Treatment options include surgical resection, bronchial artery embolization, systemic antifungal therapy and direct antifungal instillation.

**References**

1. Segal BH. Aspergillosis. *New England Journal of Medicine*. 2009 Apr 30;360(18):1870-84.
2. Russo A, Tiseo G, Falcone M, Menichetti F. Pulmonary aspergillosis: an evolving challenge for diagnosis and treatment. *Infectious Diseases and Therapy*. 2020 Sep;9(3):511-24.
3. Cadena J, Thompson GR, Patterson TF. Aspergillosis: Epidemiology, diagnosis, and treatment. *Infectious Disease Clinics*. 2021 Jun 1;35(2):415-34.
4. Denning DW, Riniotis K, Dobrashian R, Sambatakou H. Chronic cavitary and fibrosing pulmonary and pleural aspergillosis: case series, proposed nomenclature change, and review. *Clinical infectious diseases*. 2003 Oct 1;37(Supplement\_3):S265-80.
5. Panjabi C, Sahay S, Shah A. Aspergilloma formation in cavitary sarcoidosis. *Jornal Brasileiro de Pneumologia*. 2009;35:480-3.
6. Hede J, Bahot R, Shah JR. Aspergilloma in sarcoidosis. *Lung India: Official Organ of Indian Chest Society*. 2009 Oct;26(4):127.
7. Zoumot Z, Mann BS. A severe case of multisystem sarcoidosis complicated by aspergillosis and aspergillomas. *Case Reports*. 2011 Jun 9;2011:bcr1220103641.
8. Agarwal R. Allergic bronchopulmonary aspergillosis. *Chest*. 2009 Mar 1;135(3):805-26.
9. Kousha M, Tadi R, Soubani AO. Pulmonary aspergillosis: a clinical review. *European Respiratory Review*. 2011 Sep 1;20(121):156-74.
10. Passera E, Rizzi A, Robustellini M, Rossi G, Della Pona C, Massera F, Rocco G. Pulmonary aspergilloma: clinical aspects and surgical treatment outcome. *Thoracic surgery clinics*. 2012 Aug 1;22(3):345-61.
11. Rafferty P, Biggs BA, Crompton GK, Grant IW. What happens to patients with pulmonary aspergilloma? Analysis of 23 cases. *Thorax*. 1983 Aug 1;38(8):579-83.
12. Jewkes J, Kay PH, Paneth M, Citron KM. Pulmonary aspergilloma: analysis of prognosis in relation to haemoptysis and survey of treatment. *Thorax*. 1983 Aug 1;38(8):572-8.

13. Lang M, Lang AL, Chauhan N, Gill A. Non-surgical treatment options for pulmonary aspergilloma. *Respiratory Medicine*. 2020 Apr 1;164:105903.
14. Corr P. Management of severe hemoptysis from pulmonary aspergilloma using endovascular embolization. *Cardiovascular and interventional radiology*. 2006 Oct;29(5):807-10.
15. Denning DW, Cadranel J, Beigelman-Aubry C, Ader F, Chakrabarti A, Blot S, Ullmann AJ, Dimopoulos G, Lange C. Chronic pulmonary aspergillosis: rationale and clinical guidelines for diagnosis and management. *European Respiratory Journal*. 2016 Jan 1;47(1):45-68.
16. Patterson TF, Thompson III GR, Denning DW, Fishman JA, Hadley S, Herbrecht R, Kontoyiannis DP, Marr KA, Morrison VA, Nguyen MH, Segal BH. Practice guidelines for the diagnosis and management of aspergillosis: 2016 update by the Infectious Diseases Society of America. *Clinical infectious diseases*. 2016 Aug 15;63(4):e1-60.
17. Kohno S, Izumikawa K, Ogawa K, Kurashima A, Okimoto N, Amitani R, Kakeya H, Niki Y, Miyazaki Y, Japan Chronic Pulmonary Aspergillosis Study Group. Intravenous micafungin versus voriconazole for chronic pulmonary aspergillosis: a multicenter trial in Japan. *Journal of Infection*. 2010 Nov 1;61(5):410-8.

## Blast Crisis

*Continued from page 5*

it is important to evaluate for secondary complications such as disseminated intravascular coagulation (DIC), tumor lysis syndrome (TLS), bleeding from thrombocytopenia, and end-organ damage from leukostasis. An infectious workup may also be warranted, given that these patients are at higher risk for infection with dysfunctional circulating immune cells and possible functional asplenia.<sup>16,18</sup>

## Treatment

Treatment of CML in the ED should focus on management of serious complications in consultation with hematology-oncology. The most common causes of death in patients with CML in blast phase are infection due to functional neutropenia, and hemorrhage due to thrombocytopenia or DIC.<sup>16,21</sup> Thus, aggressive evaluation and management of infectious sources should be undertaken, and transfusion of blood products should be discussed with hematology-oncology to define appropriate transfusion thresholds. In some cases, transfusion of blood products worsens hyperviscosity and should be avoided.<sup>16</sup>

In patients with hyperleukocytosis, cytoreduction should be initiated to mitigate end-organ damage from leukostasis.<sup>16</sup> Treatment options (other than induction chemotherapy) include hydroxyurea, intravenous fluids, and leukapheresis.<sup>16,19,20</sup> Hydroxyurea is a cytoreductive agent that serves as bridge to definitive therapy in reducing circulating leukocytes.<sup>16,20</sup> Fluids can be used for rehydration and decreasing blood viscosity. Leukapheresis can effectively lower the WBC count from 10-70% after just one treatment, but its effects on morbidity and mortality are uncertain.<sup>19</sup> In addition, leukapheresis involves multiple risks including anticoagulation, hypocalcemia, worsening of thrombocytopenia, and the need for central venous access, and as such, it is a treatment that can be considered but not routinely recommended.<sup>16</sup> Dexamethasone is also frequently used as an adjunct to reduce inflammatory effects.<sup>16</sup>

Definitive treatment for CML involves tyrosine kinase inhibitors (TKIs), which target the pathologic BCR-ABL tyrosine kinase through competitive inhibition at ATP binding sites.<sup>2</sup> The advent of this therapy in 1999 has revolutionized the treatment of CML and greatly improved its prognosis, reducing progression from CML chronic phase (CP) to CML blast phase (BP) from 20% annually to 1-3% annually.<sup>16</sup> Imatinib, one of the first TKIs to be developed, has been largely replaced by other agents such as nilotinib and dasatinib.<sup>22</sup> CML-BP often involves a combination of TKI and additional chemotherapy, and intrathecal prophylaxis is indicated given the high risk for occult central nervous system involvement and subsequent relapse.<sup>16</sup> Most patients who progress to CML-BP require bone marrow transplant.<sup>16</sup>

## Summary

Chronic myelogenous leukemia is a hematologic malignancy associated with the Philadelphia chromosome and the Bcr-Abl1 protein. Patient presentations are varied and can include constitutional symptoms, bleeding, leukostasis, DIC, and TLS. Diagnosis is made using CBC, peripheral smear, bone marrow biopsy and cytogenetic testing in conjunction with hematology/oncology. ED management focuses on complications, with ultimate treatment including tyrosine kinase inhibitors, chemotherapy, and bone marrow transplant.

## References

1. Ren R. Mechanisms of BCR-ABL in the pathogenesis of chronic myelogenous leukaemia. *Nature Reviews Cancer*. 2005 Mar;5(3):172-83.
2. Apperley JE. Chronic myeloid leukaemia. *The Lancet*. 2015 Apr 11;385(9976):1447-59.
3. Liu K, Hu J, Wang X, Li L. Chronic myeloid leukemia blast crisis presented with AML of t (9; 22) and t (3; 14) mimicking acute lymphocytic leukemia. *Journal of Clinical Laboratory Analysis*. 2019 Oct;33(8):e22961.
4. Chen Y, Wang H, Kantarjian H, Cortes J. Trends in chronic myeloid leukemia incidence and survival in the United States from 1975 to 2009. *Leukemia & Lymphoma*. 2013 Jul 1;54(7):1411-7.
5. Miller KD, Siegel RL, Lin CC, Mariotto AB, Kramer JL, Rowland JH, Stein KD, Alteri R, Jemal A. Cancer treatment and survivorship statistics, 2016. *CA: a cancer journal for clinicians*. 2016 Jul;66(4):271-89.
6. Deininger MW, Goldman JM, Melo JV. The molecular biology of chronic myeloid leukemia. *Blood, The Journal of the American Society of Hematology*. 2000 Nov 15;96(10):3343-56.
7. Howell DA, Warburton F, Ramirez AJ, Roman E, Smith AG, Forbes LJ. Risk factors and time to symptomatic presentation in leukaemia, lymphoma and myeloma. *British journal of cancer*. 2015 Sep;113(7):1114-20.
8. Quintás-Cardama A, Cortes JE. Chronic myeloid leukemia: diagnosis and treatment. *Mayo Clinic Proceedings* 2006 Jul 1 (Vol. 81, No. 7, pp. 973-988). Elsevier.
9. Arber DA, Orazi A, Hasserjian R, Thiele J, Borowitz MJ, Le Beau MM, Bloomfield CD, Cazzola M, Vardiman JW. The 2016 revision to the World Health Organization classification of myeloid neoplasms and acute leukemia. *Blood, The Journal of the American Society of Hematology*. 2016 May 19;127(20):2391-405.
10. Bandyopadhyay D, Manna S, Hajra A, Bhattacharya TD. Atypical CML with massive splenic infarct: an extremely rare presentation. *Case Reports*. 2015 Nov 12;2015:bcr2015212821.
11. Jafferhoy S, Chantry A, Atkey N, Turner D, Wyld L. Spontaneous splenic rupture: an unusual presentation of CML. *Case Reports*. 2011 Jan 1;2011:bcrcr20113879.
12. Kumar S, Bansal D, Prakash M, Sharma P. Avascular necrosis of femoral head as the initial manifestation of CML. *Pediatric Hematology and Oncology*. 2014 Sep 1;31(6):568-73.
13. Sharma SR, Dey B. Blast crisis of chronic myeloid leukemia initially presenting as severe acute intracerebral hemorrhage. *Journal of Family Medicine and Primary Care*. 2020 Feb;9(2):1266.
14. Lakhotia M, Pahadiya HR, Prajapati GR, Choudhary A, Gandhi R. Spontaneous soft tissue haematoma—a rare presentation of chronic myeloid leukemia (CML). *Journal of Clinical and Diagnostic Research: JCDR*. 2015 Jul;9(7):OD03.
15. Porcu P, Cripe LD, Ng EW, Bhatia S, Danielson CM, Orazi A, McCarthy LJ. Hyperleukocytosis and leukostasis: a review of pathophysiology, clinical presentation and management. *Leukemia & Lymphoma*. 2000 Jan 1;39(1-2):1-8.
16. Assi R, Short N. Blast Crisis of Chronic Myeloid Leukemia (CML) A Digest for Intensivists. *Oncologic Critical Care*. 2020;1135-45.
17. Kantarjian H, Cortes J. Chronic Myeloid Leukemia. In: Jameson J, Fauci AS, Kasper DL, Hauser SL, Longo DL, Loscalzo J, eds. *Harrison's Principles of Internal Medicine*, 20e. McGraw Hill; 2018.
18. Hehlmann R. How I treat CML blast crisis. *Blood, The Journal of the American Society of Hematology*. 2012 Jul 26;120(4):737-47.
19. Bruserud Ø, Liseth K, Stammesfset S, Cacic DL, Melve G, Kristoffersen E, Hergiv T, Reikvam H. Hyperleukocytosis and leukocytapheresis in acute leukaemias: experience from a single centre and review of the literature of leukocytapheresis in acute myeloid leukaemia. *Transfusion Medicine*. 2013 Dec;23(6):397-406.
20. Lewis MA, Hendrickson AW, Moynihan TJ. Oncologic emergencies: pathophysiology, presentation, diagnosis, and treatment. *CA: a cancer journal for clinicians*. 2011 Sep;61(5):287-314.
21. Jonte F, Fernández-Fuertes F, Cecchini C, Luño E, Ordóñez A, Fernández C, Suarez P, Lausín A, Fernández J. Cause of death, survival, and prognostic factors in a series of 98 patients with chronic myeloid leukemia. *Sangre*. 1992 Oct 1;37(5):351-4.
22. Kantarjian HM, Larson RA, Cortés JE, Deering KL, Mauro MJ. Current practices in the management of chronic myeloid leukemia. *Clinical Lymphoma Myeloma and Leukemia*. 2013 Feb 1;13(1):48-54.

## Polycythemia

*Continued from page 7*

toms are present in approximately one third of patients with PV at the time of diagnosis and can often precede other manifestations of the disease by months to years.<sup>3,4</sup> Erythromelalgia is considered to be pathognomonic for PV and is described as an intense burning pain, often isolated to the hands and feet, associated with either rubor or pallor of those extremities.<sup>4</sup> In patients with erythromelalgia, there is no evidence of neurovascular dysfunction.

Patients with absolute polycythemia may present with acute thrombotic events. Between 7 and 16 percent of patients with PV are noted to have an arterial or venous thrombotic event at or before the time of diagnosis.<sup>5</sup> These events more commonly occur in the mesenteric, hepatic or portal vasculature. In patients who are young, female or otherwise relatively healthy and without comorbidities, new diagnoses of Budd-Chiari syndrome, portal vein thrombosis or mesenteric ischemia should trigger concern for a possible hyperviscous state such as polycythemia vera.<sup>6</sup> Absolute polycythemia is a known risk factor for pulmonary embolism, deep vein thrombosis, acute myocardial infarction and ischemic stroke.

## Management and Disposition

Patients with relative polycythemia do not typically require further evaluation or admission for polycythemia alone. ED evaluation of patients with incidentally-discovered, asymptomatic absolute

polycythemia can reasonably be limited to a CBC, renal profile and walking pulse oximetry, with consideration for carboxyhemoglobin levels.

Patients with polycythemia have up to a 28% incidence of thrombotic events and an approximately 8% chance of a major hemorrhage related to their disease.<sup>4</sup> Therefore, admission is appropriate for symptomatic patients, either with hallmark signs of PV or with hyperviscosity symptoms, and for patients with hematocrit >60g/dl. These patients can be started on low-dose aspirin in the emergency department, which provides symptomatic relief and decreases the thrombotic risk.<sup>7</sup>

Acute thrombi in patients with polycythemia are managed similarly to patients who lack this risk factor, with the exception of phlebotomy. Phlebotomy is indicated for patients with thrombotic complications and to maintain normal hematocrit levels in patients with primary polycythemias. While the need for phlebotomy may be an indication for admission, it is generally considered to be outside the scope of practice of an emergency physician. General guidance suggests that during the diagnostic workup phase, phlebotomy can be used to lower hematocrit levels to <60% until definitive diagnosis is reached, after which target hematocrit should be approximately 45%.<sup>8</sup> Phlebotomy treatments involve the removal of large quantities of blood, usually 250-500 cc, followed by 1:1 replacement with a crystalloid fluid. Conventional wisdom is that the expected reduction in hematocrit is three percentage points per 500mL blood removed. Dual-antiplatelet agents are not routinely recommended in patients with polycythemia due to an increased risk of hemorrhage, but there is some evidence that this may be helpful in certain patients.<sup>9</sup>

### Summary

Polycythemia is most frequently found incidentally, and can be relative or absolute. Absolute polycythemia has both primary and secondary causes, and if left unmanaged can cause symptoms of hyperviscosity and increased risk of thrombotic events. Treatment depends on the underlying cause and may include anti-platelet agents and phlebotomy.

### References

1. Djulbegovic M, Dugdale LS, Lee AI. Evaluation of Polycythemia: A Teachable Moment. *JAMA internal medicine*. 2018 Jan 1;178(1):128-30.
2. Sullivan KM, Mei Z, Grummer-Strawn L, Parvanta I. Haemoglobin adjustments to define anaemia. *Tropical Medicine & International Health*. 2008 Oct;13(10):1267-71.
3. Siegel FR, Tauscher J, Petrides PE. Aquagenic pruritus in polycythemia vera: characteristics and influence on quality of life in 441 patients. *American journal of hematology*. 2013 Aug;88(8):665-9.
4. Yesilova AM, Yavuzer H, Cengiz M, Toprak ID, Hanedar E, Ar MC, Baslar Z. Analysis of thrombosis and bleeding complications in patients with polycythemia vera: a Turkish retrospective study. *International journal of hematology*. 2017 Jan

- 1:105(1):70-8.
5. Tefferi A, Rumi E, Finazzi G, Gisslinger H, Vannucchi AM, Rodeghiero F, Randi ML, Vaidya R, Cazzola M, Rambaldi A, Gisslinger B. Survival and prognosis among 1545 patients with contemporary polycythemia vera: an international study. *Leukemia*. 2013 Sep;27(9):1874-81.
6. Landolfi R, Di Gennaro L, Nicolazzi MA, Giarretta I, Marfisi R, Marchioli R. Polycythemia vera: gender-related phenotypic differences. *Internal and emergency medicine*. 2012 Dec;7(6):509-15.
7. Van Genderen PJ, Mulder PG, Waleboer M, Van De Moesdijk D, Michiels JJ. Prevention and treatment of thrombotic complications in essential thrombocythemia: efficacy and safety of aspirin. *British journal of haematology*. 1997 Apr;97(1):179-84.
8. Marchioli R, Finazzi G, Specchia G, Cacciola R, Cavazzina R, Cilloni D, De Stefano V, Elli E, Iurlo A, Latagliata R, Lunghi F. Cardiovascular events and intensity of treatment in polycythemia vera. *N Engl J Med*. 2013 Jan 3;368:22-33.
9. Pedersen OH, Larsen ML, Kristensen SD, Hvas AM, Grove EL. Recurrent cardiovascular events despite antiplatelet therapy in a patient with polycythemia vera and accelerated platelet turnover. *The American journal of case reports*. 2017;18:945.
10. Caporale CM, Notturmo F, Caulo M, Uncini A. Capsular warning syndrome mimicking a jacksonian sensory march. *J Neurol Sci*. 2009;285(1-2):262-264.
11. Camps-Renom P, Delgado-Mederos R, Martínez-Domeño A, Prats-Sánchez L, Cortés-Vicente E, Simón-Talero M, ... Martí-Fàbregas J. (2015). Clinical Characteristics and Outcome of the Capsular Warning Syndrome: A Multicenter Study. *International Journal of Stroke*, 10(4), 571-575. <https://doi.org/10.1111/ijfs.12432>
12. Paul NLM, Simoni M, Chandratheva A, Rothwell PM. Population-based study of capsular warning syndrome and prognosis after early recurrent TIA. *Neurology*. 2012;79(13):1356-1362.
13. Kamo H, Miyamoto N, Otani H, Kurita N, Nakajima S, Ueno Y, et al. The Importance of Combined Antithrombotic Treatment for Capsular Warning Syndrome. *Journal of Stroke and Cerebrovascular Diseases*. 2018;27(11):3095-9.
14. Vivanco-Hidalgo RM, Rodríguez-Campello A, Ois A, et al. Thrombolysis in capsular warning syndrome. *Cerebrovasc Dis*. 2008;25(5):508-510.
15. Pan Y, Elm JJ, Li H, et al. Outcomes Associated With Clopidogrel-Aspirin Use in Minor Stroke or Transient Ischemic Attack: A Pooled Analysis of Clopidogrel in High-Risk Patients With Acute Non-Disabling Cerebrovascular Events (CHANCE) and Platelet-Induced Inhibition in New TIA and Minor Ischemic Stroke (POINT) Trials. *JAMA Neurol*. 2019;76(12):1466-1473. doi:10.1001/jamaneurol.2019.2531
16. Case courtesy of Dr C. Iglar, Radiopaedia.org, rID: 42143

## Ocular Toxoplasmosis

Continued from page 9

### Summary

*T. gondii* is a ubiquitous protozoan that can present as an acquired or congenital infection and is of particular concern in immunocompromised patients. Ocular toxoplasmosis is the most common cause of posterior uveitis in the world. The diagnosis of ocular toxoplasmosis can be made clinically and dilated fundoscopic exam is the key to diagnosis. If the diagnosis is uncertain, serology or direct testing can be helpful. In immunocompetent individuals this is usually a self-limited disease. Patients who are immunocompromised, pregnant, or present with severe disease require treatment, usually with pyrimethamine, sulfadiazine, and folinic acid. Steroids are often added to help with ocular inflammation in the treatment of ocular toxoplasmosis.

### References

1. Maenz M, Schlüter D, Liesenfeld O, Schares G, Gross U, Pleyer U. Ocular toxoplasmosis past, present and new aspects of an old disease. *Progress in retinal and eye research*. 2014 Mar 1;39:77-106.
2. Tenter AM, Heckeroth AR, Weiss LM. *Toxoplasma gondii*: from animals to humans. *International journal of parasitology*. 2000 Nov 1;30(12-13):1217-58.
3. Jones JL, Holland GN. Annual burden of ocular toxoplasmosis in the United States. *American Journal of Tropical Medicine and Hygiene*. 2010 March; 82(3): 464-465.
4. Montoya JG, Liesenfeld O. Toxoplasmosis. *Lancet*. 2004 June 12; 363(9245): 1965-1976.
5. Glasner PD, Silveira C, Kruszon-Moran D, Martins MC, Burnier Júnior M, Silveira S, Camargo ME, Nussenblatt RB, Kaslow RA, Bel-Fort Júnior R. An unusually high prevalence of ocular toxoplasmosis in southern Brazil. 1992 Aug 15; 114(2): 136-144.
6. Bosch-Driessen LE, Berendschot TT, Ongkosuwitto JV, Rothova A. Ocular toxoplasmosis: clinical features and prognosis of 154 patients. *Ophthalmology*. 2002 May; 109(5): 869-878.
7. Abu El-Asrar AM, Herbort CP, Tabbara KF. Differential diagnosis of retinal vasculitis. *Middle East African Journal of Ophthalmology*. 2009 Oct; 16(4): 202-218.
8. Dhakal R, Gajurel K, Pomares C, Talucod J, Press CJ, Montoya JG. Significance of a Positive Toxoplasma Immunoglobulin M Test Result in the United States. *J Clin Microbiol*. 2015 Nov; 53(11): 3601-3605.
9. Butler NB, Furtado JM, Winthrop KL, Smith JR. Ocular toxoplasmosis II: clinical features, pathology and management. *Clinical Experiment Ophthalmol*. 2014 May 21; 41(1): 95-108.
10. Holland GN, Lewis KG. An update on current practices in the management of ocular toxoplasmosis. *Am J Ophthalmol*. 2002 July; 134(1): 102-114.
11. Zhang Y, Lin X, Lu F. Current treatment of ocular toxoplasmosis in immunocompetent patients: a network meta-analysis. *Acta Trop*. 2018 Sep; 185: 52-62.
12. Jasper S, Vedula SS, John SS, Horo S, Sepah YJ, Nguyen QD. Corticosteroids as an adjuvant therapy for ocular toxoplasmosis. *Cochrane Database Syst Rev*. 2013; 4(4): CD007417.
13. Holland GN, Engstrom RE, Glasgow BJ, Berger BB, Daniels SA, Sidikaro, Harmon JA, Fischer D, Boyer DS, Rao NA. Ocular toxoplasmosis in patients with the Acquired Immunodeficiency Syndrome. *Am J Ophthalmol*. 1988; 106(6): 653-667.

### Submitted B Pod Cases

Annals of B Pod is always looking for interesting cases to publish! Please submit cases via EPIC In Basket message to AoBP Editors. Make sure to include the providers involved in the case.

Case	Providers
Blast Crisis	Frederick/Moellman
Polycythemia	Laurence/Knight
Ocular Toxoplasmosis	Makinen/Hill
Fallopian Tube Torsion	Gottula/Pomerantz
Aspergilloma	Kletsel/Gleimer/Baxter

